

SOME PATHOLOGICAL STUDIES ON MALATHION TOXICITY IN SWISS MICE

ROFAIL, S. K.

Veterinary Serum and Vaccine Research Institute, A R C, Dokki - Giza

(Manuscript received 23 May 2007)

Abstract

The present study was carried out to investigate the effect of induced Malathion toxicity on Swiss mice and the role of some antioxidant (AD3E and ascorbic acid) for protection. Histopathological examination revealed haemorrhage, severe vascular and necrotic changes prominent in the liver and heart. Analysis evoked significant increase of AST and ALT enzymes in experimental Malathion toxicity group, while, the treated group revealed mild histopathological changes and an excellent improvement in enzyme parameters.

INTRODUCTION

Pesticides continually administered over long periods, caused chronic toxicity, a matter that threatens the environment. Malathion is one of widely used organophosphorous compound insecticides. It is used for several purposes in natural life, it is used to control disease vectors.

Many investigations have been done to study the effect of Malathion alone in different species. Manifold disturbances in biochemical and histopathological picture of laboratory animal exposed to Malathion have been reported (Abdel Ghaffar, 1989 and Ibrahim *et al.*, 1991).

The chronic toxic effect of organophosphorous compound in laboratory animals produced histopathological changes including congestion of all organs, perivasculitis and degeneration of parenchymatous organs recorded by Barlas and Kolankaya (1996).

Blood parameters are sensitive to exposure to many toxic substances including insecticides. Changes in some biochemical parameters such as increase in the activity of some enzymes have been attributed to disturbance of liver function (El-Gendy, 1990).

Some reports accounted for interaction between various vitamins and minerals and insecticides indicated that malnutrition increased the susceptibility to toxicity of organophosphorous compounds, as oxidative stress is believed to play a pivotal role in pesticides induced toxicity; the effect of different antioxidants in reducing this toxicity was reported by Bagchi *et al.* (1993).

Therefore, this investigation was planned to assess histopathological aspect and enzyme evaluation in mice experimentally exposed to Malathion toxicity and the protective effect of AD3E as natural antioxidant and/or ascorbic acid supplementation in partially offsetting this toxicity.

MATERIALS AND METHODS

Laboratory Animals

This experiment was performed upon 100 healthy mice weighing 20-30 g, starting 7 days before the beginning of the experiment. The mice were housed in groups in metal cages, kept in a room under natural conditions of illumination and temperature; food and water were provided *ad-libitum*.

Malathion

It was obtained as solution containing 570 g/l of the active ingredient of Malathion. Its trade name is Nasrlathion, manufactured by Nasr Co. for Intermediate Chemicals, Abo Rawash, Egypt.

AD3E vitamin

It was obtained by Pfizer, Egypt.

Ascorbic acid vitamin

It was obtained as water soluble powder 99.7%, Riedel-Dehaen, Germany.

Experimental design

The tested animals were divided into 5 separate groups each of 20 mice. The first group was considered as a control negative group (without toxicity or treatment). Mice of other four groups were administered Malathion suspended in water at a dose of 137.5 mg/kg body weight (1/10 of non-lethal effective dose) which was previously recorded in Tomlin (1997) daily for 30 days. The second group was considered as control positive group (toxicity only). The third group was treated with AD3E at a dose of 1ml/litre in drinking water. The 4th group was treated with ascorbic acid at a dose of 200 mg/kg body weight in drinking water. The 5th group was treated with mixture of both vitamins with the same doses in 3rd and 4th groups. The treatment with the vitamins was given for 45 days after the period of Malathion administration.

Sampling

Five mice from each group were sacrificed, and collected tissue specimens from them and blood samples were collected from remaining mice at 15, 30, 45 days from beginning of the experiment.

Histopathological studies

Specimens from liver and heart were fixed in 10% neutral buffered formalin, tissue specimens were processed routinely for paraffin sections of 4-5 μm thickness, stained with haematoxylin and eosin (H & E) according to Bancroft *et al.* (1996).

Enzymes analysis

Samples were subjected to enzymes analysis for serum aspartate amino transferase (AST) and serum alanine amino transferase (ALT) according to White *et al.* (1970).

Statistical analysis

The data were analyzed using Student ANOVA test and comparison was done between means using LSD (least significant difference) at $P < 0.05$ as outlined by Petrie and Watson (1999).

RESULTS AND DISCUSSION

The extensive use of insecticides is one of the serious problems in world environment. The knowledge of their toxic potentials is necessary to protect mammals life and establish a safe use pattern for these chemicals.

Malathion as insecticide is biologically potent and this potency is not confined only to arthropods, but also, extends to animals and man. In this investigation, short term toxicity with Malathion was induced in mice, thereafter, the animals were treated with AD3E and ascorbic acid. Tissue specimens and blood samples were taken throughout the experiment for histopathological examination and enzymes analysis.

The post mortem lesions were mostly frequent in the internal organs (liver and heart). They were congested with the presence of multiple petechial haemorrhages, meanwhile, in other groups treated with vitamins, the liver and heart did not reveal significant gross lesions.

Regarding the histopathological changes in the liver and heart during the course of the experiment, there were variable degrees of tissue alterations attributed to the toxic effect of Malathion and the effect of protective agents as AD3E and ascorbic acid in revering its toxicity.

The present study revealed various degenerative and necrotic changes in the induced Malathion toxicity group of mice included liver and heart. The histopathological changes in the liver in toxicity group at 15 days of the experiment showed that the hepatocytes revealed severe dilatation of central vein. Mononuclear cells were infiltrated in the fibrous tissue of the portal triads (Fig. 1). At 30 days, the hepatic blood vessels were widely dilated. The hepatocytes revealed focal area of

necrosis (Fig. 2). In treated groups with AD3E and ascorbic acid, few mononuclear cells infiltration was observed and less evident hepatocellular necrosis (Fig. 3).

The histopathological findings in the heart of mice in induced toxicity group at 15 days, showed that the cardiac blood vessels were widely dilated and engorged with blood with haemorrhages in between the cardiac muscle fiber, the muscle fibers showed severe changes in the myocardium (Fig. 4). Some of the cardiac muscles revealed necrotic changes with mononuclear cells infiltration in between the necrotic myofibrils (Fig. 5). In treated group with vitamins AD3E and ascorbic acid, there appeared slight areas of haemorrhage and mild necrotic changes of the cardiac muscles (Fig. 6).

These changes were nearly similar to those obtained by Barlas and Kolankaya (1996). The degenerative and necrotic changes encountered in the tissue of Malathion toxicity group, were accounted by Haschk and Rousseaux (1998) to the fact that Malathion is one of the direct acting chemicals on cell constituent, meanwhile, Bulusu and Chakravarty (19984) reported that Malathion brings about injuries of the lysosomal membrane in the cytoplasm of the affected cell with subsequent release of B. glucuronidase enzyme into the cytoplasm leading to cell death and necrosis. Also, the degenerative changes were attributed to the disturbance in lipid metabolism which accompanied the toxicity with Malathion. The degenerative changes observed in this study were similar to those described with Bulusu and Chakravarty (1984).

In respect to enzymes activity, it is clear from Table 1 that there was a high increase of AST and ALT activities in experimental toxicated group when compared with control group, while, AST and ALT levels in treated group with mixture of vitamins AD3E and ascorbic acid returned almost close to the normal levels. It is well known that the determination of the activities of hepatic enzymes is indicative of hepatic toxicities (Zimmerman and Henry, 1989). The description of transaminases from the normal value denotes biochemical impairment and lesions of tissues and cellular function because they are involved in the detoxification process, Malathion and biosynthesis of energetic macro-molecular for different essential functions (Tordior and Van Heemstera-Liquin, 1980).

The augmented levels of aminotransferases may be indicative of internal organs damages specially in liver and myocardium, and the increase of AST and ALT could occur due to increased permeability and subsequent leakage of cellular enzyme (Varshneya *et al.*, 1988). Hepatotoxic action of insecticides which lead to tissue damage and necrosis seems to be indicative for elevation of liver enzymes in blood (Rahman *et al.*, 1990).

Generally, possible explanation for the protective effect of vitamins AD3E and ascorbic acid could be due to administration of excess of it during animal toxicity; this may probably influence the detoxification mechanism through activating metabolism and excretion of the insecticide as non-enzymatic component of anti-oxidant defence mechanism (Meister, 1992 and Salem *et al.*, 1992).

The results of the present study revealed that a powerful protection against the effect of Malathion toxicity on the tissue changes was achieved in the groups in which a combination of vitamins AD3E and ascorbic acid was administered. There is growing concern regarding to hazards in veterinary field resulted from chronic exposure to Malathion. From this study, it could be concluded that when Malathion is applied on mice farms, concurrent administration of AD3E and ascorbic acid is advisable to partial overcoming alterations produced by this insecticide at the metabolic and tissue levels.

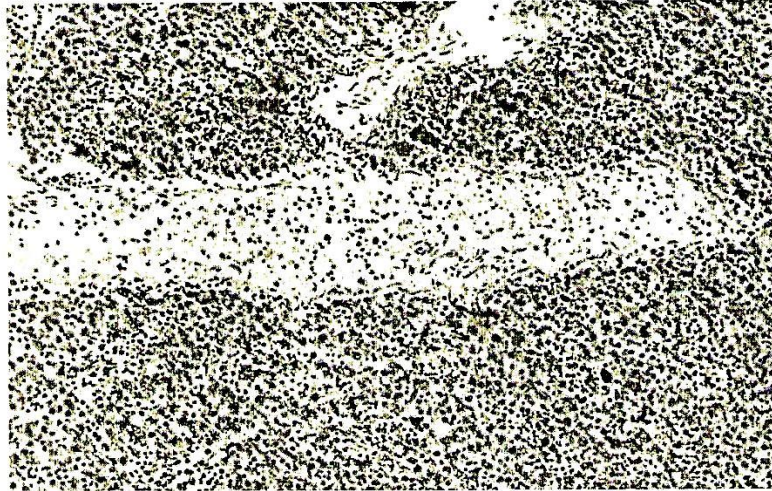


Fig. 1. Liver of mice 15 days post Malathion toxicity showing severe dilatation of the central vein impacted by blood cells associated with massive number of cells infiltration (H & E, x40)

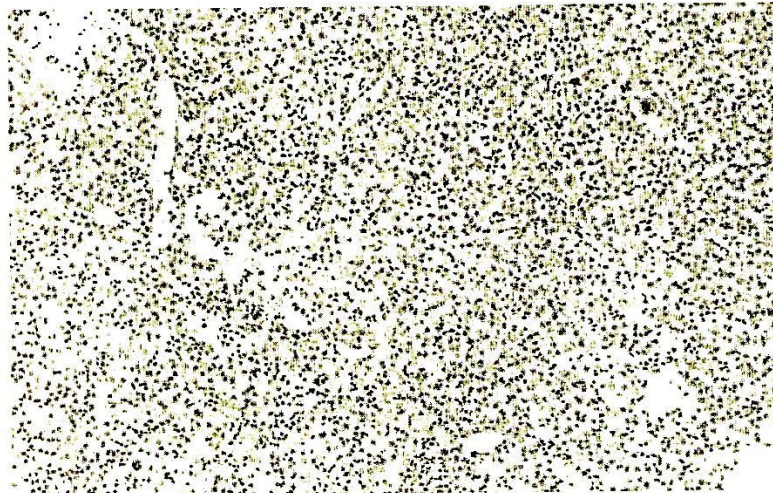

Fig. 2. Liver of mice 30 days post Malathion toxicity showing the hepatocellular necrosis, dilatation of the central vein and the mononuclear cells infiltration (H & E, x40)

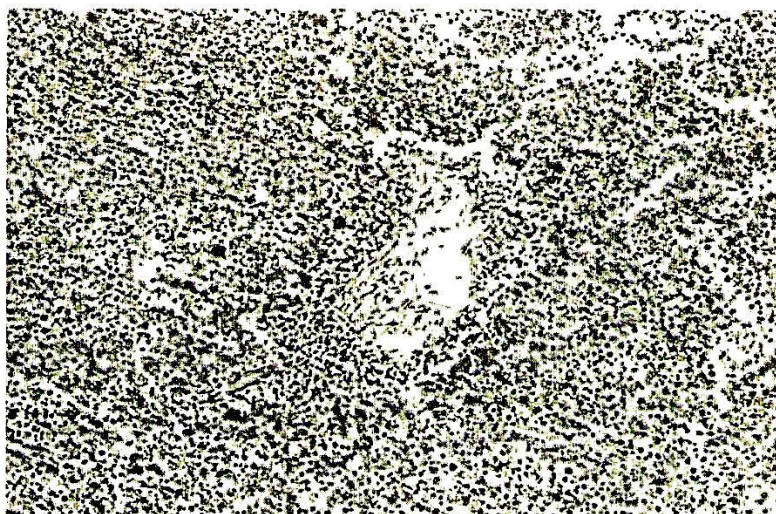

Fig. 3. Liver of mice treated with mixture of vitamins AD3E and ascorbic acid showing few cells infiltration and less necrotic changes (H & E, x40)

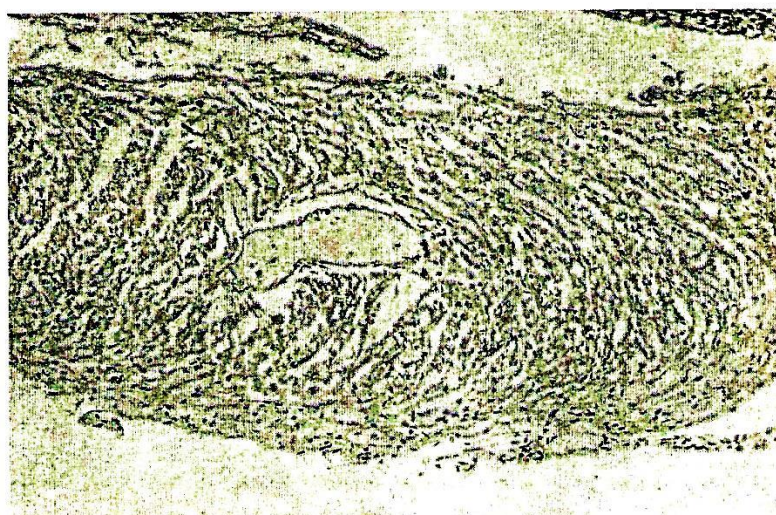


Fig. 4. Heart of mice 15 days post Malathion toxicity showing hyperemic and dilating myocardial blood vessels (H & E, x40)



Fig. 5. Heart of mice 30 days post Malathion toxicity showing mononuclear leucocytic cells infiltration in between the degenerated myocardial bundles (H & E, x40)




Fig. 6. Heart of mice treated with mixture of vitamin AD3E and ascorbic acid showing few necrotic changes (H & E, x40)

Table 1. Enzymes serum in group administered with Malathion with or without vitamin AD3E and ascorbic acid.

Group	Amino transferases (Mean \pm SD)					
	AST			ALT		
	At 15 days	At 30 days	At 45 days	At 15 days	At 30 days	At 45 days
Group (1)	6.8 \pm 1.4	6.8 \pm 1.4	6.8 \pm 1.4	7.3 \pm 1.5	7.3 \pm 1.5	7.3 \pm 1.5
Group (2)	8.6 \pm 1.1*	8.9 \pm 1.3*	9.2 \pm 0.8*	8.3 \pm 1.3	8.7 \pm 1.2	9.0 \pm 1.8*
Group (3)	8.6 \pm 1.1*	8.3 \pm 0.9*	7.6 \pm 2.3	8.7 \pm 1.2	8.3 \pm 1.3	7.9 \pm 2.2
Group (4)	8.6 \pm 1.1*	8.3 \pm 0.9*	7.6 \pm 2.3	8.7 \pm 1.2	8.3 \pm 1.3	7.9 \pm 2.2
Group (5)	8.3 \pm 0.9*	7.6 \pm 2.3	6.8 \pm 1.4	8.3 \pm 1.3	7.9 \pm 2.2	7.3 \pm 1.5

AST: Aspartate Amino transferase

ALT: Alanine Amino transferase

* Significant different from control (P < 0.05)

Group (1): Control negative group (without toxicity and treatment)

Group (2): Control positive group (received Malathion only)

Group (3): Received Malathion and treated with AD3E vitamin

Group (4): Received Malathion and treated with ascorbic vitamin

Group (5): Received Malathion and treated with mixture of AD3E and ascorbic acid vitamins

ACKNOWLEDGMENT

The author would like to thank *Prof. Dr. Maysa, M.M.*, Professor of Pathology, Animal Health Research Institute, for her advice and guidance to accomplish this work.

REFERENCES

1. Abdel Ghaffar, K. S. 1989. Pathological studies on the effect of some organophosphorus compounds (Phosfolan and Mephosfolan) on Albino rats. Thesis, M.V.Sc., Toxicology, Fac. Vet. Med., Assiut Univ.
2. Bagchi, D., E. A. Hasan, M. Bagchi and J. J. Stoks. 1993. Protective effect of antioxidants against endrin-induced hepatic lipid peroxidation, DNA damage and excretion of urinary lipid metabolites. *Free Radical. Biol. Med.*, 15 (2): 217-222.
3. Bancroft, D., A. Stevens and R. Turner. 1996. Theory and practice of histological technique. Fourth edition, Churchill, Livingstone, Edinburgh, London, Melbourne.
4. Barlas, N. E. and D. Kolankaya. 1996. A histopathological study on the effect of commercial and biogarded Malathion on liver, kidney and spleen of mice. *Turkish J. Zoology*, 20 (2): 149-154.
5. Bulusu, S. and L. Chakrovarty. 1984. Augmented hepatic susceptibility to Malathion toxicity in rats on low protein diets. *Environ. Res.*, 35 (1): 53-65.
6. El-Gendy, K. S. 1990. The effects of thiodicarb and cypermethrin on some liver enzymes of rats. *Bull. Alex. Fac. Med.*, XXXVI: 607-612.
7. Haschk, W.M. and C.G. Rousseaux. 1998. Fundamentals of toxicologic pathology. Academic Press, San Diego, London, New York, Boston, Sydney, Tokyo, Toronto.
8. Ibrahim, T. A., A. Shehata, A. Seddek and M. H. Karrou. 1991. Chronic toxicity studies of Ezalo in Albino mice. *J. Egypt. Vet. Med. Assoc.*, 51 (1-2): 639-650.
9. Meister, A. 1992. Commentary on the antioxidant effect of ascorbic acid and glutathione. *Biochem. Pharmacol.*, 44: 1905-1915.
10. Patrie, A. and P. Watson. 1999. Statistics for veterinary and animal science. 4th Ed. pp. 90-99. The Blackwell Science LTD, United Kingdom.
11. Rahman, M. F., M. K. J. Siddiqui, M. Mahboob And M. Mustafa. 1990. Haematological and hepatotoxic effect of isocarb in chicken. *J. Appl. Toxicol.*, 15 (3): 187-192.
12. Salem, H.A., S. S. El-Ballal and A. S. Seddek. 1992. The effect of AD3E vitamin mixture on experimentally induced mephosfolan short term toxicity in mice. *Assiut Vet. Med. J.*, 28 (55): 158-173.
13. Tomlin, C. 1997. The pesticide Manual. 11th Ed. Crop. Protection Publication. The Royal Society of Chemistry.
14. Tordior, W. F. and E. A. Van Heemstera-Liquin. 1980. Field studies monitoring exposure and effects in the development of pesticides. Elsevier, Amsterdam, Oxford, New York: 207.

15. Varshneya, C., H. S. Bahgaand, L. D. Sharma. 1988. Effect of dietary Malathion on hepatic microsomal drug metabolizing systems of Gallus domestics. *Toxicol. Letter*, 31: 107-111.
16. White, B.A., M.M. Erickson and S.C. Sevens. 1970. *Chemistry for medical technologists*. 3rd Ed., pp. 293-296 ECV Mosby Company, Saint Louis, USA.
17. Zimmerman, H. J. and I. B. Henry. 1989. *Clinical, enzymology in Henry, I.B. (eds) Clinical diagnosis and management by laboratory methods*. 17th Ed. p. 251-282.

دراسات على التغيرات الباثولوجية الناتجة عن السمية الأَصطناعية بالملاثيون في الفئران السويسرية

صفوت كمال روفائيل

معهد بحوث الأمصال واللقاحات البيطرية- مركز البحوث الزراعية - النقي - الحيزة

نظراً للأثار المدمرة للمبيدات الحشرية على الأجهزة المختلفة في جسم الحيوان والناتجة عن التعرض لكميات قليلة منها على فترات زمنية مختلفة أتجهنا الى إلقاء الضوء على السمية الأَصطناعية بالملاثيون في الفئران السويسرية ومدى استجابتها لبعض مضادات الأَكسدة (أد³هـ، حمض الأسكوربيك). ودلت النتائج أن هناك تغيرات هستوباثولوجية في كل من الكبد والقلب وكانت هذه التغيرات في صورة تنكز في خلايا هذه الأعضاء مع احتقان ونزيف في أوعيتها الدموية. وتأثرت وظائف الكبد بدرجة كبيرة حيث أزداد نشاط أنزيمي الاسبرتيت (AST)، الألائين (ALT) في المجموعة المسممة أَصطناعياً بالملاثيون عن المجموعات المعالجة بمضادات الأَكسدة. ومن هذه النتائج ننصح باستخدام مجموعة الفيتامينات سالفة الذكر في حالة تعرض الحيوان بصفة عامة لسمية الملاثيون.